

# Sepsis with Spreading Retropharyngeal Abscess in a Diabetic Patient with Acute Kidney Injury: A Case Report

SAYAN BHATTACHARYYA, CHANDNI SINHA, NEERAJ KUMAR, SUBHASH KUMAR

## ABSTRACT

Uncontrolled diabetes mellitus is an immunosuppressive condition and leads to many secondary infections. There can be more than one micro-organism causing multiple organ system involvement in the same patient, in these situations.

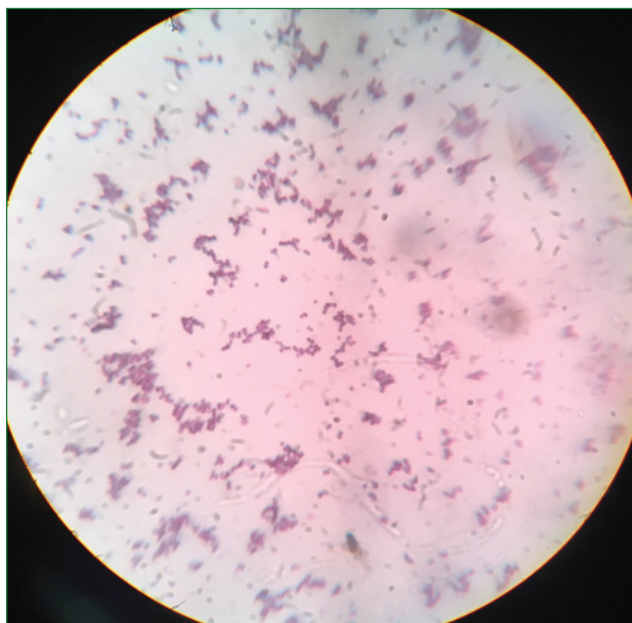
It is important to identify this problem and treat accordingly, since various micro-organisms respond differently to different antibiotics. We here report a case of retropharyngeal abscess developing in a middle aged diabetic person that presented atypically and was diagnosed later.

**Keywords:** Diabetes mellitus, Septic arthritis, *Staphylococcus aureus*

## CASE REPORT

A 50-year-old male patient presented to the outpatient department of the institute with chief complaints of progressive right infraclavicular swelling, fever, stridor and shortness of breath since 3 days. The patient was emaciated, and hypertensive (blood pressure 170/110 mmHg). He was admitted, purulent fluid drained from the abscess like lesion in right infraclavicular area and started on IV piperacillin-tazobactam, clindamycin and levofloxacin after obtaining patient's consent. The purulent fluid was sent to Microbiology laboratory of the institute after written informed consent of the patient for staining and bacterial culture and susceptibility. The fluid was yellowish and viscid, and on Gram staining, revealed copious leukocytes and many Gram positive cocci arranged in clusters. Culture was put up on blood agar, chocolate agar and Mac Conkey agar, and after overnight aerobic incubation at 37°C, pigmented, opaque, low convex colonies resembling *Staphylococcus aureus* were observed. It was slide and tube coagulase positive using pooled human plasma and fermented mannitol. The isolate was found to be susceptible to clindamycin (2 µg), levofloxacin (5 µg) and cefoxitin (30 µg) and refractory to azithromycin (15 µg) in vitro, by Kirby-Bauer disk diffusion method using *Escherichia coli* ATCC 25922 as susceptible negative control. Since, disks were working well and standard charts showing zone diameters were available, susceptible positive control was not put up simultaneously. Sputum sample was also sent and cultured, which also grew the same bacterium (*S. aureus*) with the same susceptibility pattern. Subsequently, the random blood sugar value of the patient was found to be very high (490 mg/dL). Thus, it was accidentally discovered that he was a diabetic. Total leukocyte count in blood was 20000 cells/µL, blood potassium level was 3.7 meq/L, blood urea

nitrogen level was 200 mg/dL and total serum creatinine was 8 mg/dL. Serum sodium level was within normal limits. Thus, there were indications of renal insufficiency. The next day, the patient suddenly developed ventricular fibrillation followed by sudden cardiac arrest. He was instantly resuscitated by using Cardio-Pulmonary Resuscitation (CPR) technique, intubated endotracheally and put on ventilator support. The fever did not subside, and there developed painful swelling in left knee joint. A blood sample was drawn and again sent for culture and susceptibility to Microbiology department. After 3 days of aerobic incubation at 37°C, there was heavy growth of non lactose fermenting mucoid colonies, which were identified as *Acinetobacter lwoffii* by standard biochemical methods [1]. This isolate was susceptible to ampicillin and sulbactam, tigecycline, clindamycin (2 µg), azithromycin (15 µg), ciprofloxacin (5 µg), meropenem, amikacin, cefixime, cefuroxime and cotrimoxazole by Kirby-Bauer disk diffusion method using *Escherichia coli* ATCC 25922 as susceptible negative control. The purulent fluid in left knee joint was also sent to Microbiology lab, and on Gram staining, plenty of pus cells and a few broken, Gram positive to Gram variable cocci were found [Table/Fig-1]. However, there was no bacterial growth after incubation for 72 hours at 37°C, possibly because these bacteria were dead. Sputum sample was also sent for Ziehl-Nelson (ZN) staining, but no acid fast bacilli were found. The patient slowly started improving and responding to chemotherapy; total leukocyte count was recorded as 11,000/µL after 3 days, and fever subsided. On advice of radiologist, Contrast enhanced CT-scan of neck and thorax was done, which showed a huge retropharyngeal abscess-like thickening of soft tissue extending from base of skull (clivus) upto C7, and communicating with the mediastinum and costochondral



**[Table/Fig-1]:** Gram positive cocci from colonies of *S. aureus* grown from sample.

area, with secondary fracture of first and second ribs (due to the CPR manoeuvre). Air collection was noted in the retropharyngeal area which communicated with a cavity in upper lobe of right lung. There was also atelectasis of the upper lobe of right lung. Thus, the infraclavicular swelling was probably an extension of the retropharyngeal abscess. The patient improved on follow-up and was extubated. He is now doing well.

## DISCUSSION

Diabetes mellitus is an immunosuppressive condition, due to multiple factors like reduced phagocytosis and chemotaxis of neutrophils and a shift towards humoral immunity leading to decreased intracellular killing of pathogens [2]. There has been a spurt of cases of diabetes mellitus worldwide recently, from about 170 million in 2000 to a predicted burden of 370 million by 2030 [3]. Some infections are very commonly reported in cases of uncontrolled diabetes mellitus with or without ketoacidosis, like rhinocerebral mucormycosis, malignant otitis externa and emphysematous cholecystitis [4]. Retropharyngeal Abscess (RpA) is also particularly common in diabetes mellitus where it usually develops spontaneously, found usually in males and has a high degree of morbidity and mortality [5]. We here report a case of septicaemia with retropharyngeal abscess and septic arthritis in a patient with uncontrolled diabetes mellitus and acute kidney injury. In adults, RpA frequently develops in adult patients with Diabetes mellitus, with respiratory symptoms developing in a minority of patients [6]. It is a potentially fatal deep neck space infection, usually caused by Gram positive cocci and anaerobes, and can have serious complications like jugular venous thrombosis and mediastinitis [7]. There is evidence

in scientific literature that it usually presents with unilateral neck swelling and other features [7]. It has got a more predilection to affect males than females, with about 60% of cases being recorded in males [8]. Most of the time, RPA is caused by beta-haemolytic Streptococci, *Staphylococcus aureus* and *Peptostreptococcus* sp. [7]. Usual predisposing factors or inciting events include trauma by fishbone, operative procedures and dental infections [9]. However, in children, on the other hand, it develops as a complication of upper respiratory infection or retropharyngeal lymph node abscedation [10,11]. The usual symptoms are sore throat, fever, odynophagia, dysphagia, dyspnoea but these can get masked in diabetes mellitus [9]. CT-scan can diagnose the condition but cannot distinguish it effectively from cellulitis, although the demonstration of air in retropharyngeal space by lateral X-ray neck or CT clinches the diagnosis [9]. In our case it presented in an atypical manner. Such atypical and rare complications can also appear in the form of necrotising mediastinitis, also reported in diabetes mellitus [12]. The patient developed cardiac arrest due to the septicaemia, which also possibly led to acute renal insufficiency. Stridor and dyspnoea was due to the lung atelectasis and partially also due to the uraemia following renal derangement. This case highlights the fact that RpA can present in diabetes mellitus atypically, and clinicians should be very vigilant and suspicious to diagnose it quickly and correctly and administer specific chemotherapy.

## CONCLUSION

This case report highlights the atypical presentations of RpA and also stresses the importance of clinical and microbiological readiness to identify the condition. This is the first such report from this part of the country. This condition can have multiple bacterial etiologies and is most commonly reported in uncontrolled diabetes mellitus.

## REFERENCES

- [1] Constantiniu S, Romaniuc A, Iancu LS, Filimon R, Tarași I. Cultural and biochemical characteristics of Acinetobacter spp. strains isolated from hospital units. *J Prevent Med*. 2004;12(3-4):35-42.
- [2] Tanaka Y. Immunosuppressive mechanisms in diabetes mellitus. *Nihon Rinsho*. 2008;66(12):2233-37.
- [3] Ozougwu JC, Obimba KC, Belonwu CD, Unakalamba CB. The pathogenesis and pathophysiology of type 1 and type 2 diabetes mellitus. *J Physiol Pathophysiol*. 2013;4(4):46-57.
- [4] Larkin JG, Frier BM, Ireland JT. Diabetes mellitus and infection. *Postgrad Med J*. 1985;61(713):233-37.
- [5] Afolabi OA, Fadare JO, Ogah SA, Oyewole EO. Retropharyngeal abscess in diabetics: a challenge. [Available from]: <https://pdfs.semanticscholar.org/627e/d5d4be0fdb282cb5fa4fc26d5dd56c9ceac1.pdf>
- [6] Chu FKC. Retropharyngeal abscess. *Hong Kong J Emergency Med* 2002;9(3):165-67.
- [7] Musa X, Mohamad I, Johan KB, Harun A. *Candida albicans* Retropharyngeal Abscess. *Pakistan Journal of Otolaryngology* 2014; 30:29-31.
- [8] Tannebaum RD. Adult retropharyngeal abscess: A case report

- and review of Literature. J Emerg Med. 1996;14(2):147-58.
- [9] Kokten M, Cam OH, Kilicaslan A, Hanege FM, Uzun M, Tekin M. Retropharyngeal abscess: three unusual cases. J Otolaryngology ENT Res. 2016;5(3):00144.
- [10] Hyo Y, Fukushima H, Harada T. Neck swelling from a retropharyngeal abscess caused by penicillin-resistant *Streptococcus pneumoniae*: a case report. BMC Res Notes. 2014;7:291.
- [11] Vourexakis Z, Konu P. Retropharyngeal abscess complicating 'innocent' foreign body ingestion. BMJ Case Rep. 2014; 2014: bcr2014204010.
- [12] Takao M, Ido M, Hamaguchi K, Chikusa H, Namikawa S, Kusagawa M. Descending necrotizing mediastinitis secondary to retropharyngeal abscess. Eur Respir J. 1994;7(9):1716-18.

**AUTHOR(S):**

1. Dr. Sayan Bhattacharyya
2. Dr. Chandni Sinha
3. Dr. Neeraj Kumar
4. Dr. Subhash Kumar

**PARTICULARS OF CONTRIBUTORS:**

1. Assistant Professor, Department of Microbiology, AIIMS, Patna, Bihar, India.
2. Assistant Professor, Department of Anaesthesiology, AIIMS, Patna, Bihar, India.
3. Senior Resident, Department of Anaesthesiology, AIIMS, Patna, Bihar, India.

4. Assistant Professor, Department of Radiodiagnosis, AIIMS, Patna, Bihar, India.

**NAME, ADDRESS, E-MAIL ID OF THE CORRESPONDING AUTHOR:**

Dr. Sayan Bhattacharyya,  
Assistant Professor, Department of Microbiology  
AIIMS, Patna-801507, Bihar, India.  
E-mail: sayanda7@gmail.com

**FINANCIAL OR OTHER COMPETING INTERESTS:**

None.

Date of Publishing: **Apr 15, 2018**